

# Application Of a Three-Dimensional Printed Inferior Mesenteric Artery Model in Laparoscopic Radical Resection with Preservation of Left Colic Artery for Rectal Cancer

Zongxian Zhao<sup>1\*</sup>, Zongju Hu<sup>1</sup>, Qinlingfei Liu<sup>2</sup>, Xinyu Su<sup>1</sup>, Shu Zhu<sup>1</sup>

## ABSTRACT

**Background:** Preservation of the left colic artery (LCA) reduces the incidence of anastomotic leakage (AL) in radical resection of rectal cancer (RC). However, anatomical variations in the branches of the inferior mesenteric artery (IMA) and LCA present significant surgical challenges. Here, we construct a 3D-printed IMA model to precisely determine the location and course of the LCA before surgery, and investigate the beneficial impact of this model on surgery performance.

**Methods:** We retrospectively reviewed patients with RC who received laparoscopic radical resection between January 2022 and November 2023 at Fuyang People's Hospital. Patients were divided into 3D printing group (cohort A) and control group (cohort B) and their perioperative characteristics were statistically analyzed.

**Results:** Cohort A comprised 44 patients, while cohort B consisted of 57 patients. Operating time ( $200.340 \pm 44.254$  vs.  $237.018 \pm 71.006$  min,  $p = 0.004$ ), intraoperative blood loss ( $37.500 \pm 14.480$  vs.  $63.333 \pm 25.843$  ml,  $p = 0.001$ ), duration of hospitalization ( $14.022 \pm 2.398$  vs.  $18.263 \pm 9.328$  days,  $p = 0.004$ ), and postoperative recovery time ( $8.841 \pm 2.088$  vs.  $11.461 \pm 6.602$  days,  $p = 0.014$ ) were significantly lower in cohort A than in cohort B. There were no significant differences in the number of lymph node dissections, presence of lymph vessel invasion, and AL between the two groups.

**Conclusion:** Utilization of a 3D-printed IMA model in laparoscopic radical resection of RC can assist the surgeon in understanding the LCA anatomy preoperatively, reducing intraoperative bleeding, shortening operating time, and promoting rapid postoperative recovery.

## INTRODUCTION

Rectal cancer (RC) is a common malignant tumor of the digestive tract, accounting for one-third of all morbidity and mortality due to bowel cancer, with significant implications for patient health and survival Siegel et al. (2022), Siegel et al. (2023). Alongside the increase in life expectancy, morbidity due to RC has risen gradually. Therefore, therapeutic strategies against RC have attracted growing attention. To date, treatment for RC has involved a surgery-based multidisciplinary approach, with contributions from the fields of gastroenterology, medical oncology, radiation oncology, and radiology Benson et al. (2022), Benson et al. (2020). In clinical practice, the standardization of total mesorectal excision, adoption of neoadjuvant chemoradiotherapy, implementation of rectal magnetic resonance imaging, advancements in mechanical stapling

technology, and improvements in operating techniques (transanal total mesorectal excision, TaTME; intersphincteric resection, ISR) have significantly augmented the success rates of anus-preserving surgeries for low-lying RC Piozzi et al. (2021). However, with the increased rate of anus-preserving surgery, anastomotic leakage (AL) has become a common and highly problematic postoperative complication for surgeons Karim et al. (2020). AL is identified as "communication between the intraluminal and extraluminal compartments owing to a defect of the integrity of the intestinal wall at the anastomosis between the colon and rectum or the colon and anus" Rahbari et al. (2010). Anastomotic leakage can give rise to a range of associated infectious complications, including abdominal infection, pelvic abscess, diffuse peritonitis, and sepsis, leading to prolonged hospitalization, reoperation, and even patient fatalities

<sup>1</sup>Department of Anorectal Surgery, Fuyang People's Hospital, No. 501 Sanqing Road, Yingzhou District, Fuyang, Anhui 236000, China.

<sup>2</sup>Department of Gastroenterology, Fuyang People's Hospital, No. 501 Sanqing Road, Yingzhou District, Fuyang, Anhui 236000, China.

**Correspondence to:** Zongxian Zhao, Department of Anorectal Surgery, Fuyang People's Hospital, No. 501 Sanqing Road, Yingzhou District, Fuyang, Anhui 236000, China. ORCID: 0000-0001-7553-2085. E-mail: 461901580@qq.com.

**Keywords:** Rectal cancer; Three-dimensional printing; Inferior mesenteric artery; Left colic artery.

Chadi SA et al. (2016). With advancement in surgeons' understanding of anatomy and refinement of surgical techniques, preservation of the left colic artery (LCA) has been observed to significantly mitigate the occurrence of AL following surgery Fan et al. (2018), Li et al. (2023). However, this approach is technically demanding and time-consuming, especially for the less experienced surgeon. The increased surgical difficulty is attributed to the uncertain anatomical relationship between the branches of the inferior mesenteric artery (IMA), including the LCA, sigmoid artery (SA), and superior rectal artery (SRA) Wang et al. (2018), Luo et al. (2021), Chen et al. (2022). Studies have identified three vascular types, namely, type I, LCA arising independently from IMA; type II, LCA and SA branching from a common trunk of the IMA; and type III, LCA, SA, and SRA branching at the same location (Supplementary Figure 1) Wang et al. (2018), Chen J et al. (2022), Kobayashi M et al. (2006). In addition, the distance at which the LCA emanates from the IMA differs among RA patients Zhou et al. (2022), Ke et al. (2017). The preoperative identification of the location of the LCA and the precise types of branches of the IMA are crucial for ensuring successful surgical intervention. Three-dimensional (3D) printing technology can be utilized for preoperative simulation and intraoperative navigation, assisting surgeons in selecting the appropriate surgical plan Khorsandi et al. (2019), Zoabi et al. (2022). To date, 3D printing technology has been extensively applied in orthopedics, stomatology, neurosurgery, hepatobiliary surgery, and other fields Witowski et al. (2017), Meng et al. (2023). However, its application in RC surgery is still at an early stage. In previous studies, researchers printed entire models of the pelvic cavity to guide surgery; however, this was costly and time-consuming, and therefore not convenient for clinical application Lu et al. (2023). Besides, although a monolithic 3D-printed pelvic cavity is helpful to the surgeon in understanding pelvic structure, it provides relatively little information on the local vascular anatomy. In this study, we constructed a 3D-printed IMA model to clarify the morphology of IMA branches and locate the origin of the LCA before surgery. Furthermore, we assessed the role of the 3D-printed model in augmenting auxiliary operating skill and navigation performance during RC surgery.

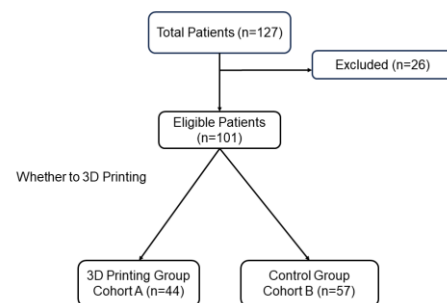
## MATERIALS AND METHODS

### Patients And Study Design

In this retrospective study, we systematically reviewed patients with RC who received laparoscopic radical resection with or without preoperative 3D printing, between January 2022 and November 2023 at Fuyang People's Hospital. Inclusion criteria were as follows: (1) patients >18 years old; (2) RC confirmed by histopathology; (3) patients provided informed and written consent for surgery; (4) patients received laparoscopic radical resection of RC with reconstruction

of the digestive tract (Dixon); (5) R0 resection was achieved; (6) patients exhibited optimal cardiac and pulmonary function; and (7) all patients underwent an abdominal double-phase enhanced scan before surgery. Exclusion criteria were as follows: (1) occurrence of distant metastasis; (2) presence of other concurrent malignancies; (3) surgical procedures without reconstruction of the digestive tract (Miles or Hartmann); (4) co-morbidity with autoimmune disease; (5) co-morbidity with severe heart and lung disease; (6) co-morbidity with schizophrenia or other mental health disorders, lack of independent behavior ability, or inability to cooperate with treatment. Among the 127 patients with RC that were screened, 101 met the above criteria and were included in the study. Patients with RC who received laparoscopic radical resection with preoperative 3D printing were grouped into cohort A (n=44) and those (n=57) who received laparoscopic radical resection without preoperative 3D printing were grouped into cohort B (Figure 1). This study was approved by the Ethics Committee of Fuyang People's Hospital hospital.

**Figure 1:** Flowchart of the study population. 3D, three-dimensional. Including patients with rectal cancer who received laparoscopic radical resection between January 2022 and November 2023 at Fuyang People's Hospital

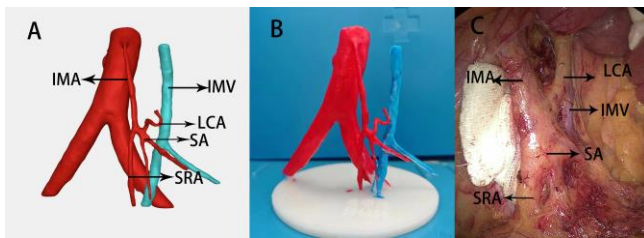


### Construction of 3D IMA Model

The CT images were imported into 3D modeling software (3D slicer 5.2.2, mimics 19.0) in DICOM format for 3D reconstruction. The abdominal aorta, left iliac artery, right iliac artery, IMA, LCA, SA, SRA, and mesenteric inferior vein (IMV) were examined and chosen for 3D reconstruction. The surface of the 3D virtual model was subsequently refined through a smoothing process. After ensuring the absence of any structural deformation or deviation, the resin white material was 3D-printed using a high-precision SLA photocuring process (CHUNLEI SLA 600). The 3D models were then cured, polished, and colored. Red was used to color the arteries and blue was used to color the veins. The completed model was submitted to the surgeon prior to surgery for preoperative assessment and surgical planning. The model was positioned adjacent to the laparoscopic television

monitor for intraoperative guidance of the location of origin and course of the LCA and types of IMA. A comparison between photos obtained during operation and the 3D printing IMA model is shown in Figure 2.

**Figure 2:** Clinical application of 3D IMA model in laparoscopic radical resection with preservation of LCA: A, Reconstruction image of IMA; B, 3D printed model of IMA; C, real photo of IMA and branches in laparoscopic RC surgery.



### Observation Index

The general characteristics of the two groups were comprehensively evaluated based on five factors, namely, gender, age, clinical stage, diverting stoma, and IMA types. The factors selected for further analysis included the operating time, intraoperative blood loss, number of lymph node dissections, lymph vessel invasion and nerve invasion, depth of tumor invasion (T stage),

presence of lymph node metastasis (N stage), duration of stay in the hospital, postoperative recovery time, cost, and occurrence of AL.

### Statistical Analysis

Using GraphPad Prism 8 software for statistical analysis, the measurement data were analyzed by Student's t test or Mann–Whitney U test. The enumeration data were analyzed by chi-square test or Fisher's exact test. Values of  $p < 0.05$  were considered to indicate statistical significance.

## RESULTS

### Clinical Characteristics

Between January 2022 and November 2023, 101 RC patients were enrolled. Among them, 44 patients who received laparoscopic radical resection without the preoperative 3D printed IMA model were enrolled in cohort A while 57 patients who received laparoscopic radical resection without the preoperative 3D printed IMA model were enrolled in cohort B. The two groups had similar clinical characteristics, including sex, age, clinical stage, diverting stoma, and IMA types ( $p > 0.05$ ). Their clinical characteristics are detailed in Table 1.

**Table 1:** Baseline Characteristics of Included RC Patients

Characteristic	Cohort A (n = 44)	Cohort B (n = 57)	t/c2	P value
Age (years)				
Mean (SD)	64.022 ± 9.790	64.684 ± 10.384	0.322	0.748
Median (IQR)	61.5 (58.5, 72.25)	68 (59, 71)		0.636
Gender			0.416	0.677
Male	26	56		
Female	18	21		
Clinical stage			1.618	0.445
I	15	21		
II	17	15		
III	13	21		
Diverting stoma			1.16	0.246
Yes	26	40		
No	18	17		
IMA types			0.649	0.723
I	25	29		
II	9	11		
III	10	17		

### Perioperative Characteristics

Patient perioperative characteristics are shown in Table 2. Operating time ( $200.340 \pm 44.254$  min in cohort A,  $237.018 \pm 71.006$  min in cohort B,  $p = 0.004$ ) and intraoperative blood loss ( $37.500 \pm 14.480$  mL in cohort A,  $63.333 \pm 25.843$  ml in cohort B,  $p = 0.001$ ) were significantly lower in cohort A than in cohort B. There were no significant differences between the two cohorts in number of lymph node dissections, lymph vessel

invasion and nerve invasion, depth of tumor invasion, presence of lymph node metastasis, and occurrence of AL. Duration of hospitalization ( $14.022 \pm 2.398$  days in cohort A,  $18.263 \pm 9.328$  days in cohort B,  $p = 0.004$ ), postoperative recovery time ( $8.841 \pm 2.088$  days in cohort A,  $11.461 \pm 6.602$  days in cohort B,  $p = 0.014$ ), and cost (thousand RMB) ( $37.230 \pm 4.620$  in cohort A,  $40.854 \pm 10.556$  in cohort B,  $p = 0.038$ ) were significantly lower for cohort A than for cohort B.

**Table 2:** Perioperative Characteristics of RC Patients

Characteristic	Cohort A (n = 44)	Cohort B (n = 57)	t/c2	P value
Operating time (min)				
Mean (SD)	$200.340 \pm 44.254$	$237.018 \pm 71.006$	2.973	0.004
Median (IQR)	195 (167.5, 232.5)	240 (190, 255)		0.003
Intraoperative blood loss (ml)	$37.500 \pm 14.480$	$63.333 \pm 25.843$	5.89	0.001
Number of lymph node dissections				
	$14.700 \pm 4.750$	$14.333 \pm 5.034$	0.373	0.71
Lymph vessel invasion				
Yes	7	16		
No	37	41		
Nerve invasion				
Yes	6	13		
No	38	44		
T				
T1/T2	18	21	0.416	0.677
T3	26	36		
N				
N0	31	36	0.769	0.442
N+	13	21		
Postoperative recovery time (days)				
Mean (SD)	$8.841 \pm 2.088$	$11.461 \pm 6.602$	2.507	0.014
Median (IQR)	8 (7.75, 10)	9 (8, 11)		0.013
Duration of stay in the hospital (days)				
Mean (SD)	$14.022 \pm 2.398$	$18.263 \pm 9.328$	2.915	0.004
Median (IQR)	14 (12.75, 15.25)	15 (12, 21)		0.046
Cost (thousand RMB)				
Mean (SD)	$37.230 \pm 4.620$	$40.854 \pm 10.556$	2.105	0.038
Median (IQR)	36.708 (35.195, 39.575)	38.830 (36.172, 42.760)		0.024
Anastomotic leakage				
Yes	1	5		
No	43	52		

## DISCUSSIONS

In clinical practice, preservation of the anus and reconstruction of the digestive tract have consistently been pivotal aspects of RC surgery. With the advancement and implementation of neoadjuvant therapy, total neoadjuvant therapy, anal preservation techniques (ISR, TaTME), and minimally invasive techniques, the rate of organ preservation is improving gradually Piozzi et al. (2021), Ghadimi M et al. (2022). However, AL as a common and serious postoperative complication, has become a major concern for surgeons. Further studies have found that preserving the LCA can increase blood supply to the anastomosis and reduce the risk of AL. However, the LCA exhibits a high rate of anatomical variation, posing significant challenges in surgical procedures. The preoperative identification of the location and variations of the LCA are therefore critical. In this study, an IMA model was constructed using 3D printing technology. The types of IMA and variation of LCA were determined before surgery. The 3D-printed model effectively guided surgeons in locating LCA accurately, thereby reducing operating time ( $200.340 \pm 44.254$  vs.  $237.018 \pm 71.006$  min,  $p < 0.05$ ) and intraoperative blood loss ( $37.500 \pm 14.480$  vs.  $63.333 \pm 25.843$  mL,  $p < 0.05$ ). Therefore, the present 3D printed model can reduce surgical complexity and enhance operative safety. Some researchers have also suggested that the utilization of 3D printing models could enhance the comprehension and assessment of blood vessels, thereby effectively mitigating intraoperative hemorrhage. This notion is consistent with the findings of our study Lu F et al. (2023), Mari et al. (2013). Although contrast-enhanced CT scan can detect the LCA, it is difficult for surgeons to mentally visualize in the form of accurate 3D images. Furthermore, it is easy to forget the specific location of the LCA based on CT scans because surgeons tend to direct their focus to the surgical procedure being carried out. In this study, we 3D-printed accurate IMA models before surgery and placed the 3D models next to the laparoscopic television monitor during the operation. This enabled the LCA to be readily identified by comparing the anatomical features of the IMA with the 3D model during the surgical procedure. The 3D-printed model of the IMA exhibits superior precision and practicability and requires a shorter printing duration than the previously reported 3D model of the entire pelvis Lu F et al. (2023). Consequently, the IMA model holds greater potential for clinical application. In this study, we found that the duration of hospitalization ( $14.022 \pm 2.398$  vs.  $18.263 \pm 9.328$  days  $p < 0.05$ ), postoperative recovery time ( $8.841 \pm 2.088$  vs.  $11.461 \pm 6.602$  days  $p < 0.05$ ), and cost ( $37.230 \pm 4.620$  vs.  $40.854 \pm 10.556$ ,  $p < 0.05$ ) for the IMA model cohort were significantly lower than for the control cohort. Identification of the location of LCA and IMA branches before operation allows the surgeon to formulate a personalized and specific surgical plan, avoid

excessive traction of the LCA during surgery, and reduce the thermal injury to the LCA from the ultrasonic and electric scalpels, in accordance with the concept of enhanced recovery after surgery (ERAS) Aarts et al. (2012). Furthermore, our analysis did not reveal a significant reduction in the incidence of AL with the implementation of 3D-printed IMA models, which can be attributed to the limited sample size across the included studies. During the course of our study, we found that the 3D IMA model was more useful for less experienced surgeons than experienced surgeons. We speculate that this is because the model might shorten the learning curve for surgeons, although this requires further study. However, this study still has some limitations: (1) this study is a retrospective analysis conducted at a single center with a limited sample size; (2) the printing material is inelastic and cannot be pulled or valgus as in the operation; (3) the models only focus on the branches of IMA and LCA, and other concerns during the operation are not addressed.

## CONCLUSION

The utilization of a 3D printed IMA model in laparoscopic radical resection of RC can greatly aid the surgeon in comprehending the intricate anatomy of the LCA prior to surgery, thereby reducing intraoperative bleeding, shortening operating time, and facilitating rapid postoperative recovery of patients.

## DECLARATIONS

### Acknowledgments

None.

### Conflicts of Interest

The authors declare that they have no conflict of interest.

### Funding

This study was funded by the Scientific Research Department of Fuyang People's Hospital, the General Surgery Department of Fuyang People's Hospital, the Health Commission of Fuyang City, and the Bengbu Medical College under award numbers FY2021-18 and 2022byzd16.

### Data Availability

The data that support the findings of this study are available from the corresponding author upon reasonable request.

### Ethical Approval

All procedures involving human participants were in accordance with the ethical standards of the institutional and national research committees and Helsinki Declaration and its later amendments. The study was approved by the institutional review board.

## Informed Consent

The patient all signed the consent form for the publication. Patient anonymity has been maintained.

## REFERENCES

1. Siegel RL, Miller KD, Fuchs HE, et al. 2022 Jan. Cancer statistics, 2022. *CA Cancer J Clin.* 72(1):7-33.
2. Siegel RL, Miller KD, Wagle NS, et al. 2023 Jan. Cancer statistics, 2023. *CA Cancer J Clin.* 73(1):17-48.
3. Benson AB, Venook AP, Al-Hawary MM, et al. 2022 Oct. Rectal cancer, Version 2.2022, NCCN Clinical Practice Guidelines in Oncology. *J Natl Compr CancNetw.* 20(10):1139–1167.
4. Benson AB, Venook AP, Al-Hawary MM, et al. 2020 Jul. NCCN guidelines insights: rectal cancer, Version 6.2020. *J Natl Compr Canc Netw.* 18(7):806-815.
5. Piozzi GN, Baek SJ, Kwak JM, et al. 2021 Sep 24. Anus-preserving surgery in advanced low-lying rectal cancer: a perspective on oncological safety of intersphincteric resection. *Cancers (Basel).* 13(19):4793.
6. Karim A, Cubas V, Zaman S, et al. 2020 Jun. Anastomotic leak and cancer-specific outcomes after curative rectal cancer surgery: a systematic review and meta-analysis. *Tech Coloproctol.* 24(6):513-525.
7. Rahbari NN, Weitz J, Hohenberger W, et al. 2010 Mar. Definition and grading of anastomotic leakage following anterior resection of the rectum: a proposal by the International Study Group of Rectal Cancer. *Surgery.* 147(3):339-51.
8. Chadi SA, Fingerhut A, Berho M, et al. 2016 Dec. Emerging trends in the etiology, prevention, and treatment of gastrointestinal anastomotic leakage. *J Gastrointest Surg.* 20(12):2035-2051.
9. Fan YC, Ning FL, Zhang CD, et al. 2018 Apr. Preservation versus non-preservation of left colic artery in sigmoid and rectal cancer surgery: a meta-analysis. *Int J Surg.* 52:269-277.
10. Li Z, Zhou Y, Xu L, et al. 2023 Jul. Safety and efficacy of left colic artery preservation in laparoscopic anterior resection for lower rectal cancer. *Future Oncol.* 19(21):1485-1494.
11. Wang KX, Cheng ZQ, Liu Z, et al. 2018 Aug 28. Vascular anatomy of inferior mesenteric artery in laparoscopic radical resection with the preservation of left colic artery for rectal cancer. *World J Gastroenterol.* 24(32):3671-3676.
12. Luo Y, Li R, Wu D, et al. 2021 Feb 17. Long-term oncological outcomes of low anterior resection for rectal cancer with and without preservation of the left colic artery: a retrospective cohort study. *BMC Cancer.* 21(1):171.
13. Chen J, Wang M, Chen Y, et al. 2022 Sep 12. A clinical study of inferior mesenteric artery typing in laparoscopic radical resections with left colonic artery preservation of rectal cancer. *World J Surg Oncol.* 20(1):292.
14. Kobayashi M, Morishita S, Okabayashi T, et al. 2006 Jan 28. Preoperative assessment of vascular anatomy of inferior mesenteric artery by volume-rendered 3D-CT for laparoscopic lymph node dissection with left colic artery preservation in lower sigmoid and rectal cancer. *World J Gastroenterol.* 12(4):553-5.
15. Zhou J, Chen J, Wang M, et al. 2022 Mar 8. A study on spinal level, length, and branch type of the inferior mesenteric artery and the position relationship between the inferior mesenteric artery, left colic artery, and inferior mesenteric vein. *BMC Med Imaging.* 22(1):38.
16. Ke J, Cai J, Wen X, et al. 2017 May. Anatomic variations of inferior mesenteric artery and left colic artery evaluated by 3-dimensional CT angiography: insights into rectal cancer surgery - A retrospective observational study. *Int J Surg.* 41:106-111.
17. Khorsandi D, Fahimipour A, Abasian P, et al. 2021 Mar 1. 3D and 4D printing in dentistry and maxillofacial surgery: printing techniques, materials, and applications. *Acta Biomater.* 122:26-49.
18. Zoabi A, Redenski I, Oren D, et al. 2022 Apr 24. 3D printing and virtual surgical planning in oral and maxillofacial surgery. *J Clin Med.* 11(9):2385.
19. Witowski JS, Coles-Black J, Zuzak TZ, et al. 2017 Dec. 3D printing in liver surgery: a systematic review. *Telemed J E Health.* 23(12):943-947.
20. Meng M, Wang J, Huang H, et al. 2023 Sep 1. 3D printing metal implants in orthopedic surgery: methods, applications and future prospects. *J Orthop Translat.* 42:94-112.
21. Lu F, Qiu L, Yu P, et al. 2023 Jun 19. Application of a three-dimensional printed pelvic model in laparoscopic radical resection of rectal cancer. *Front Oncol.* 13:1195404.
22. Ghadimi M, Rödel C, Hofheinz R, et al. 2022 Aug 22. Multimodal treatment of rectal cancer. *Dtsch Arztebl Int.* 119(33-34):570-580.
23. Mari FS, Nigri G, Pancaldi A, et al. 2013 Jun. Role of CT angiography with three-dimensional reconstruction

of mesenteric vessels in laparoscopic colorectal resections: a randomized controlled trial. *Surg Endosc.* 27(6):2058-67.

24. Aarts MA, Okrainec A, Glicksman A, et al. 2012 Feb.

Adoption of enhanced recovery after surgery (ERAS) strategies for colorectal surgery at academic teaching hospitals and impact on total length of hospital stay. *Surg Endosc.* 26(2):442-50.